








RESEARCH

Open Access



Spinopelvic alignment and low back pain after total hip arthroplasty: a scoping review

Mohammadreza Pourahmadi¹ , Mohammad Sahebalam¹, Jan Dommerholt^{2,3,4} , Somayeh Delavari⁵ 
, Mohammad Ali Mohseni-Bandpei^{6,7} , Abbasali Keshtkar⁸ , César Fernández-de-Las-Peñas^{9,10}  and
Mohammad Ali Mansournia^{11*} 

Abstract

Objective: Spinopelvic alignment is increasingly considered as an essential factor for maintaining an energy-efficient posture in individuals with normal or pathological status. Although several previous studies have shown that changes in the sagittal spinopelvic alignment may occur in patients undergoing total hip arthroplasty (THA), no review of this area has been completed so far. Thus, the objective of this scoping review was to summarize the evidence investigating changes in spinopelvic alignment and low back pain (LBP) following THA.

Data sources: We adhered to the established methodology for scoping reviews. Four electronic databases were systematically searched from inception-December 31, 2021.

Study selection: We selected prospective or retrospective observational or intervention studies that included patients with THA.

Data extraction: Data extraction and levels of evidence were independently performed using standardized checklists.

Data synthesis: A total of 45 papers were included in this scoping review, involving 5185 participants with THA. Pelvic tilt was the most common parameter measured in the eligible studies ($n = 26$). The results were not consistent across all studies; however, it was demonstrated that the distribution of pelvic tilt following THA had a range of 25° posterior to 20° anterior. Moreover, decreased sacral slope and lower pelvic incidence were associated with increased risk of dislocation in patients with THA. Lumbar spine scoliosis did not change significantly after THA in patients with bilateral hip osteoarthritis (5.50°(1.16°) vs. 3.73°(1.16°); P -value = 0.29). Finally, one study indicated that LBP improvement was not correlated with postoperative changes in spinopelvic alignment parameters. Several methodological issues were addressed in this study, including no sample size calculation and no type-I error adjustment for outcome multiplicity.

Conclusions: Changes in spinopelvic alignment may occur after THA and may improve with time. Patients with a THA dislocation usually show abnormal spinopelvic alignment compared to patients without a THA dislocation. LBP usually improves markedly over time following THA.

Keywords: Arthroplasty, Replacement, Hip, Spinopelvic alignment, Spine, Low back pain, Review

Background

Assessment of spinopelvic alignment is gaining increasing importance and attention, not only in spinal surgery but also in hip surgery [1]. Spinopelvic alignment is a complex chain of correlations from the spine to

*Correspondence: mansournia_ma@yahoo.com

¹¹ Department of Epidemiology and Biostatistics, School of Public Health, Tehran University of Medical Sciences, Poursina St., Shanzdah-e Azar St., O. Box: 6446-14155, Tehran, Iran

Full list of author information is available at the end of the article



the pelvis and that changes in one region of the spine can result in reciprocal changes in other spinopelvic regions with potential alignment consequences [2]. The literature has shown that imbalanced spinopelvic alignment is associated with worse function and poor quality of life in patients with spine and hip disorders [3]. Hence, efficient performance of daily human activities requires an ideal coordinated motion between the spine, pelvis, and hips. A good example of normal relative motion between the adjacent segments is stand-to-sit movement, in which flattening (or flexion) of the lumbar spine, a posterior tilt of the pelvis, and flexion of the hips happen [4]. Spinopelvic alignment and kinematic imbalance following total hip arthroplasty (THA) may change the functional position of the acetabulum, creating a potential for dislocation [5, 6].

THA is one of the most common, cost-effective, and clinically successful surgeries performed today for the treatment of arthritic hip disorders [7–9]. It provides reliable outcomes for patients suffering from end-stage degenerative hip osteoarthritis (OA), especially pain relief, functional restoration, and overall improved quality of life [8]. Although THA is referred to as ‘*the operation of the century*’ in 2007 [10], it not without potential complications and consequences. Healy et al. (2016) [9] listed the potential complications of THA including bleeding, wound complication, thromboembolic disease, neural deficit, periprosthetic fracture, dislocation or instability, abductor muscle disruption, deep periprosthetic joint infection, vascular injury, implant loosening, osteolysis, and so forth. Furthermore, changes in the spinopelvic alignment may occur in patients after THA [11]. Heckmann et al. (2018) [6] alleged that spinopelvic imbalance may serve as a causative factor for late dislocations after THA. Lateral spine-pelvis-hip radiographs may provide a radiographic explanation for both instability and the direction of the dislocation. Various spinopelvic alignment parameters have been evaluated before or after THA, including pelvic incidence (PI), pelvic tilt (PT), sacral slope (SS), sagittal vertical axis (SVA), lumbar lordotic (LL) angle, thoracic kyphosis (TK) angle, and coronal lumbar angles [6, 11–13]. The PI, which is the algebraic sum of the PT and SS, is a constant morphologic parameter that helps clinicians to predict the physiologic individual sagittal range of motion of the pelvis [14]. The PI does not change with different ages and in between the sexes [15], and it is an important parameter for determining the spinal balance [16]. The PT, SS, and LL angle are functional parameters with body position-dependent values [14]. Available literature suggests that abnormal spinal alignment may be associated with LBP [17]. It is also reported that the

prevalence of LBP among patients undergoing THA varies between 21.2 and 60.4% [18].

Due to the importance of spinopelvic alignment and kinematics following THA, this scoping review was conducted to identify and summarize the existing literature and indicate methodological gaps in the available body of knowledge before providing a framework for future research. Scoping reviews are a form of knowledge synthesis that address an exploratory research question, often aiming to approach complicated, broad, or fragmented areas of research that have not received much attention in the literature [19]. Since there are no published systematic reviews on this topic, this scoping review aims to provide a comprehensive overview of spinopelvic alignments and low back pain (LBP) following THA. In this scoping review we did not assess the relationship between spinopelvic alignment and LBP following THA.

Methods

One reviewer (M.P.) conducted an exhaustive scoping search once the authors decided on the aim of the review. Thus, authors ensured that the objective had not been addressed by previous reviews. This scoping review used the framework proposed by Arksey and O’Malley (2005) [20], with consideration given to suggestions from Levac et al. (2010) [21] to guide the methodology. A scoping review does not require ethical approval and patient consent since it does not include any new data collection. Because PROSPERO does not currently accept protocols for scoping reviews, a review protocol was not registered in any registry. We reported following the Preferred Reporting Items for Systematic Reviews and Meta-Analyses extension for Scoping Reviews Checklist [22]. Five steps were followed:

- i) Identify the research question
- ii) Identify relevant studies
- iii) Study selection
- iv) Chart the data
- v) Collate, summarize, and report the results

Identify the research question

Our research questions were as follows:

- What are the volume, yearly distribution, spinopelvic alignment parameters, and LBP measured in previously published studies in the field of THA?
- What critical areas of methodological improvement are needed to optimize the quality of future studies?

To formulate a search strategy for the current scoping review, the PI/ECOT(S) method was employed, as described by Sackett et al. (2000) [23].

P (Population)—participants of all ages who had undergone THA (10th revision, 2020 ICD-10-CM diagnosis code Z96.64). In the present study, THA was defined as surgery in which the diseased ball and socket of the hip joint are completely removed and replaced with artificial materials. No restriction for the reason of THA was imposed. No studies were included in which only surface replacement arthroplasty (SRA) of the hip was performed.

I/E (Intervention/Exposure)—a THA procedure with no limitation on approach performed (i.e., anterior, posterior, or lateral) and materials and implants being used.

C (Comparator)—any comparator; no comparator.

O (Outcomes)—the outcomes of this scoping review were LBP and spinopelvic parameters. Spinopelvic parameters extracted in this scoping review are defined in Table 1.

T (Time)—all studies were considered; studies were not limited according to time of follow-up.

S (Study design)—Studies with the design of clinical trials and observational (i.e., cohort, cross-sectional, and case-control) were considered eligible. Articles published only as conference proceedings/abstracts, narrative reviews, systematic reviews, news/magazine articles, case reports, or where only published in protocol stage were excluded.

Identifying relevant studies

Licensed journal databases

One author (M.P.) systematically searched for peer-reviewed articles, from inception to December 31, 2021, in the following licensed databases: PubMed/MEDLINE, Scopus, Embase[®], and the Cochrane Central Register of Controlled Trials (CENTRAL). Electronic search strategies were constructed based on the combined keywords: *hip, arthroplasty, low back pain, spinopelvic alignment, and spinopelvic range of motion* to identify human studies that measured spinopelvic alignment and ROM following THA. A combination of Medical Subject Headings (MeSH; MEDLINE), Emtree medical (Embase[®]) terms, and free text words in research equations with 'OR' and 'AND' Boolean operators were used. Free text words were selected from the indexed keywords of most relevant original studies and reviews (e.g., [24–27]) in Scopus. Free text words were also selected from the synonyms of all keywords used in the text of relevant studies. Search terms around the types of study were not used to prevent limiting the search. The search strategy was initially created in PubMed/MEDLINE (NLM) and then translated into the other databases. Details of PubMed/MEDLINE

(NLM) database and other databases search syntaxes are presented in Supplement file 1. We did not review content from file sources that were from mainstream publishers (e.g., Sage, Wiley, ScienceDirect, Springer, Taylor & Francis, and BMJ), as we expected these to be captured in our broader search strategy. Our searches had no language restrictions.

Grey literature

We searched for ongoing and unpublished studies in the Register for Clinical Trials (<https://clinicaltrials.gov/>) and the WHO's International Clinical Trials Registry Platform (<https://www.who.int/ictrp/en/>).

Hand searching

Citation tracking in Scopus and reference list scanning of the selected studies and relevant reviews were checked for eligible studies to ensure comprehensiveness. Additionally, the table of contents of the *Journal of Arthroplasty* and the *Journal of Bone & Joint Surgery—American Volume* was reviewed.

Study selection

After completion of all database searches, the citations were imported into the EndNote reference management software (version X9.1; Clarivate Analytics Inc., Philadelphia, PA, USA), where duplicate citations were removed automatically and double-checked manually. Articles were assessed for inclusion through a two-stage process. The first stage screening was of titles and abstracts and was done independently by two reviewers (M.P. and M.S.). Any disputes were discussed until a consensus was reached between the reviewers. If consensus was not possible, a final decision was made by a third expert reviewer (A.K.). If a study met all of the criteria, then the full text of the study was assessed for eligibility. Furthermore, a full-text review was undertaken if the title and abstract did not provide adequate information. A table named "list of excluded articles with reasons" was also established for the excluded studies.

Chart the data

Data extraction

Data abstraction from the selected articles was carried out by two reviewers (M.P. and M.S.), as suggested by Arksey and O'Malley (2005) [20]. An electronic spreadsheet (Microsoft Excel, Microsoft Office 365, Redmond, WA, USA) was designed according to the objectives specified in this scoping review, and the following data were extracted: study design, number of included participants, objective(s) of the study, arthroplasty approach, outcomes of the study, key finding(s), and any other relevant details. The data extraction tool was piloted with

Table 1 Spinopelvic alignment parameters definitions and their normative ranges/values

Spinopelvic parameter	Definition	Normative range/values
Cervical lordosis (CL)	The angle between the lines tangent to the posterior aspect of C ₂ and C ₇ vertebral bodies [80].	20° – 35° [81]
Thoracic kyphosis (TK)	The angle between the superior endplate of T ₅ and the superior endplate of T ₁₂ [16].	20° – 45° [82]
Lumbar lordosis (LL)	The angle between the superior endplate of L ₁ and the superior endplate of S ₁ [16].	So wide (30° – 80° using the Cobb method) [83]
Lumbar scoliosis	A lateral curvature of the lumbar spine with torsion of the spine and a disturbance of the sagittal profile [84]. Lumbar scoliosis is measured using the Cobb angle, which is the angle between the two most tilted vertebrae of a given scoliotic curve as measured on a coronal radiograph [85].	Cobb angle > 10° in skeletally mature patients [86]
T ₁ spinopelvic inclination (T ₁ Spi)	The angle between the line drawn from the centroid of T ₁ and the center of the bicoxofemoral axis and the vertical plumb line [87].	–13° – +5° (average = –4.67°) [88]
Pelvic tilt (PT)	The angle between the vertical line and line joining the middle of sacral endplate to the center of the bicoxofemoral axis [89].	13° (6°) [90]
T ₁ pelvic angle (TPA)	The angle between the line from the femoral head axis to the centroid of T ₁ and the line from the femoral head axis to the middle of the S ₁ endplate [88].	–6° – +25° (average = 8.28°) [88]
Sacral slope (SS)	The angle between the superior endplate of S ₁ and a horizontal reference on sagittal imaging of the lumbosacral spine [89].	Approximately 33° – 49° (average = 41°) [90]
Pelvic incidence (PI)	The angle between the line perpendicular to the sacral endplate at its midpoint and the line connecting this point to the axis of the femoral heads [89]. Pelvic incidence = sacral slope + pelvic tilt [56].	Approximately 45° – 65° (average = 55°) [90]
Pelvic inclination angle (PIA)	The angle between the line connecting the anterior boarder of the sacral promontory with the upper border of the symphysis and a horizontal line [91].	60° [91]
Anterior pelvic plane angle (APP)	The angle between the vertical line and the line connecting the pubic symphysis and the bilateral anterior superior iliac spine midpoint (anterior pelvic plane) [16, 57].	–5° – +5° [16]
Sagittal vertical axis (SVA)	Distance between the C ₇ plumb line and the postero-superior edge of S ₁ [92].	< 30 mm [93]
Spinocrural angle (SSA)	The SSA angle is defined by the angle connecting the center of the C ₇ vertebra to the center of the S1 endplate and the line parallel to the superior S ₁ endplate [94].	135° (8°) [94]
Cup/ acetabular (lateral) inclination (CI)	The angle between the transverse axis and the articular side of the acetabular cup. Measurement of this angle can be done by drawing a line through the medial and lateral margins of the cup and measuring the angle with the transischial tuberosity line [95].	30° – 50° [75]
Functional cup (acetabular) inclination (FI)	The angle between the pelvic longitudinal axis and the acetabular axis when this is projected onto the coronal plane [29].	43.7° – 55.9° [96]
Sagittal plane cup anteversion (CA)	The angle between the line tangent to the anterior and posterior edges of the acetabulum and the horizontal plane [97]. In the transverse plane, it is the angle formed by the line tangent to the anterior and posterior edges of the acetabulum and the sagittal axis [97].	5° – 25° [30]

Table 1 (continued)

Spinopelvic parameter	Definition	Normative range/values
Functional cup (acetabular) anteversion (FCA)	The angle can be calculated using the Lewinnek's formula: cup anteversion angle = $\arcsin(D_1/D_2)$. D_1 is the distance of the short axis of an ellipse drawn perpendicular to the long axis of the acetabular component and D_2 is the distance of the long axis [31].	It depends on several variables such as planned inclination, planned anteversion, standing pelvic tilt, and sitting pelvic tilt [98]

three articles of varied methodological approaches in order to ensure it would collect the correct and effective information. This process was verified by one researcher (M.P.). It was an iterative process in which there were many changes during each round. Any disagreements were resolved by consensus. Following the completion of the data extraction process, one author (M.P.) double-checked the extracted data as a quality control. As customary with scoping reviews, eligible studies were not formally assessed for risk of bias. However, the Oxford Centre for Evidence-Based Medicine (CEBM) grade of evidence was used for the assessment of each included study. Levels of evidence ranged from one to five, with one indicating the highest quality of evidence and five indicating the lowest quality of evidence (eTable 1).

Collating, summarize, and report the results

This study employed a '*descriptive-analytical*' method within the narrative tradition to summarize the data and include the following:

- Descriptive numerical analysis: The nature and distribution of the included articles were assessed concerning the total number of articles, year of publication, country of origin, study population, study design, and journals where the articles were published.
- Narrative summary of included study findings: We reported the studies' results according to the present study outcomes. Where relevant and where possible, we extracted the point estimates and 95% confidence intervals/ standard deviations provided.
- Implication of results: We reported the findings according to our objective of describing the published literature on spinopelvic alignment changes after THA. Furthermore, we identified the gaps in the current literature base.

Results

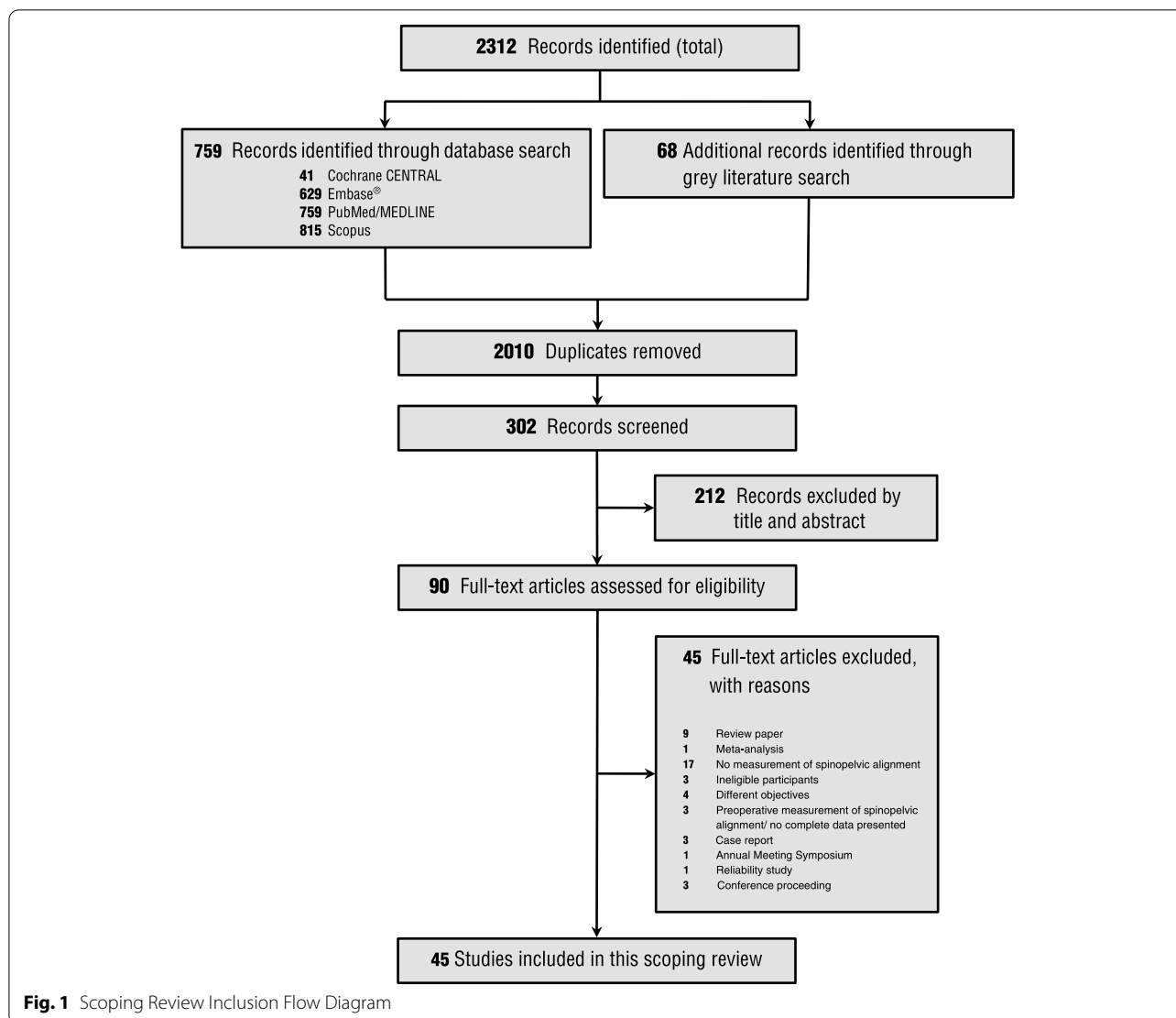
Papers designs and participants

From 2312 identified records, we selected 90 full-text reports (Fig. 1). Forty-five papers were excluded for the reasons summarized in Fig. 1 and eTable 2. Overall, data

were extracted from 45 papers (Fig. 1). About 78% of the included papers were conducted in the United States and Japan. The Journal of Arthroplasty published around 22% of the included papers (eTable 3). Forty-four out of 45 studies (~98%) were published in English, and one paper was published in Japanese [28]. The original studies sample sizes varied from 20 to 509 with a median [interquartile range; IQR] of 84 [50–138]. Most papers included participants ≥ 60 years of age. Lateral and anterolateral approach surgeries for THA were commonly performed [16, 17, 29–42]. Reassessments using radiographic images were performed between 0 to 120 months after THA with a median and IQR of 12 and 6–24, respectively. Details of the references are provided in Additional file 2. Additionally, A review of grey literature identified several relevant records in this area (eTable 4). According to Oxford Centre for Evidence-Based Medicine criteria, 21 papers met Level 2 level of evidence [6, 16, 32, 33, 35, 37, 41–55], while 24 papers met Level 3 due to retrospective nature and quality of the study [3, 11, 17, 28–31, 34, 36, 38–40, 56–67].

Spinopelvic alignments and LBP

PT was the most commonly parameter measured by the included studies ($n=26$), followed by SS ($n=25$), PI ($n=20$), LL ($n=19$), cup (acetabular) anteversion (CA; $n=14$), and cup (acetabular) inclination (CI; $n=12$) (Table 2). Pelvic motion were measured in only one study [47]. Moreover, LBP was measured in eight studies [11, 17, 32, 39, 41, 53, 55, 65]. The results revealed that there is controversy about the spinopelvic alignment parameters in patients with THA. Carender et al. (2020) [66] reported that the prevalence of decreased spinopelvic motion was 34.2% in 228 patients who underwent primary THA. Three studies showed that the distribution of PT following THA had a range of 25° posterior to 20° anterior [35, 49, 60]. In a study conducted by Kanto et al. (2019) [16], changes in PT were observed postoperatively in 59% of included patients. Furthermore, some studies reported that patients with high degrees of posterior PT showed an increased posterior PT 5–10 years after THA [35, 60]. Fixed posterior PT during standing, lower LL, and decreased SS were also demonstrated in patients with anterior dislocations



[6, 45]. Marratt et al. (2015) [29] indicated that preoperative PT is strongly correlated with postoperative PT ($r^2=0.88$; P -value = 0.0001). The preoperative sagittal anterior pelvic plane angle (APP) was the only predictive factor associated with a marked anterior or posterior change in PT [16]. Additionally, changes in SS, TK, and SVA parameters were correlated with changes in APP ($r^2 \geq -0.215$; P -value ≤ 0.032) [16].

Decreased SS and lower PI are associated with increased risk of dislocation in patients with THA [56]. Patients with dislocations usually have lower SS and higher PI minus LL (PI-LL) compared to patients without dislocations [58]. Although Kanto et al. (2019) [16] reported that the SS was significantly decreased postoperatively (P -value = 0.003), Furuichi et al. (2016) [57] stipulated that impaired SS was improved in 41% of patients after THA.

The available literature suggests that body position can change spinopelvic alignments following THA. In a study conducted by Nam et al. (2017) [50], it has been also reported that the change in standing to sitting SS was significantly less in patients with a lumbar fusion ($9.8^\circ \pm 8.2^\circ$) and history of prosthetic dislocation ($12.5^\circ \pm 4.7^\circ$) versus patients without a history of lumbar surgery undergoing THA (P -value < 0.001 and P -value = 0.008). Tamura et al. (2016) [60] showed that PI in the sagittal plane was significantly lower in the standing position compared to the supine position (P -value < 0.01). Moreover, standing sagittal plane CA differed from supine anteversion by greater than 5° in more than 50% of patients in a study done by Polkowski et al. (2012) [48]. Tezuka (2014) [28] found similar results and mentioned that CA and CI were higher in the standing position compared to the supine position in patients after THA. It is worth mentioning

Table 2 (continued)

Study	Spinopelvic alignments and LBP																		
	CL	TK	LL	Scoliosis	LBP	SVA	SSA	T ₁ -Spi	SS	PI	PT	PIA	TPA	APP	CA	Acetabular (lateral) inclination	Functional cup (acetabular) anteversion	Functional cup (acetabular) inclination	Pelvic motion
Maratt et al., 2015									✓	✓	✓	✓	✓	✓	✓			✓	
Tezuka, 2014												✓							
Radcliff et al., 2013			✓					✓											
Murphy et al., 2013										✓									
Polkowski et al., 2012															✓				
Taki et al., 2012										✓									
Lazennec et al., 2011															✓				
Ishida et al., 2011											✓								
Zhu et al., 2010											✓								
Parvizi et al., 2010																			
Blondel et al., 2009																			
DiGioia et al., 2006																			
Nishihara et al., 2003																			✓

Abbreviations: APP sagittal anterior pelvic plane, CA cup anteversion, C₇ cup inclination, CL cervical lordosis, FI functional inclination, LBP low back pain, LL lumbar lordosis, PI pelvic incidence, PIA pelvic inclination angle, PT pelvic tilt, SS sacral slope, SVA sagittal vertical axis, T₁-Spi T₁-spinopelvic inclination, TK thoracic kyphosis, TPA T₁ pelvic angle

that Tripuraneni et al. (2016) [61] did not find a significant difference in CI and CA between direct anterior and posterior approaches (P -value ≥ 0.12).

Functional cup anteversion (FCA) was another parameter measured by Okanou et al. (2017) [31]. The angle was increased significantly over the 10-year follow-up compared to that at three weeks after surgery (P -value < 0.01). Preoperative posterior PT in the standing position and vertebral fractures after THA were significant predictors of increasing FCA (P -value ≤ 0.011) [31]. It has been also indicated there are marked differences in the relationship between FCA and PT in patients with severe lumbar degenerative disc disease compared with healthy control [51].

Patients with THA and LBP generally show increased TPA compared to patients without LBP (15.7° vs. -1.37°). LBP relief occurred in patients after THA [17]; however, Eyvazov et al. (2016) [32] declared that the improvement in LBP levels was not correlated with postoperative changes in spinopelvic alignment, including PI, PT, SS, CA, and CI (P -value ≥ 0.052). In a recent study, Okuzu et al. (2021) [39] concluded that among patients with LBP before THA, 62.9% had improved LBP at 1 year after THA. The preoperative factors associated with LBP improvement of LBP were a low Cobb angle (odds ratio [OR]=0.95; 95% CI=0.91–0.98); P -value < 0.01) and high APP angle (OR=1.04; 95% CI=1.00–1.08); P -value=0.03) [39]. Moreover, patients with persistent LBP had a significantly lower APP angle (-6.0° (10.3°)), lower LL (38.4° (20.7°)), greater SVA (45.2 mm (21.6 – 70.9 mm)), and greater PI-LL mismatch (9.3° (-1.1° to 24.9°)) [39].

In a study performed in Japan, THA improved lumbar spine scoliosis since the Cobb angle was changed significantly from 45.81° to 43.70° in patients with unilateral hip OA [11]. Nevertheless, the results obtained from patients with bilateral hip OA showed that lumbar spine scoliosis did not change significantly after THA [preoperative angle= 5.50° (1.16°); postoperative angle= 3.73° (1.16°); P -value=0.29] [11].

Other sagittal spine alignments such as CL and TK were assessed in the available literature [32], and only TK had significant changes following THA (P -value=0.042) [32]. Changes in spinopelvic alignments following THA with their relevant essential details are presented in Additional file 2.

Methodological pitfalls among the included studies

Except for Klemm et al. (2020) [51] and Tripuraneni et al. (2016) [61], none of the selected studies employed a priori sample size calculations, and no post hoc power calculations were performed to determine whether the sample size was adequate to evaluate spinopelvic alignment

changes and LBP following THA. The included studies did not specify the primary and secondary outcome measures, and the level of significance (α level) was not adjusted in the majority of outcome measures. Finally, the method of sampling was not indicated clearly in the majority of the studies, thereby the generalizability of results could be affected.

Discussion

One of the main objectives of this scoping review was to assess the volume, yearly distribution, spinopelvic alignment parameters, and LBP measured in the published papers in the field of THA. Scoping reviews are a useful method when an overview is required to outline future research priorities by establishing what evidence is currently available [20, 68] or when limited evidence exists. This study highlights that a vast number of spinopelvic alignment parameters have been assessed in the published literature (Additional file 2). However, the results were not consistent across all studies for some spinopelvic alignment parameters.

We included in this scoping review 45 original studies published between 2003 and 2021. There has been a marked increase in publications since, with 73% of reviewed papers published between 2015 and 2021.

LBP was one of the outcomes measured in this study. Eguchi et al. (2018) [11] reported that severe hip OA may be associated with LBP and the authors demonstrated that THA could improve LBP in patients following THA. The authors suggested that the mechanism of LBP improvement following THA may be related to compensatory lumbar scoliosis improvement [11]. In addition, Eyvazov et al. (2016) [32] reported that changes in other spinopelvic alignment parameters were not correlated with LBP improvement in 28 patients after THA. However, the results of this study may be influenced by the limited sample size and high variability of the data [17]. Ben-Galim et al. (2007) [69], in a prospective cohort study on 25 patients undergoing THA, observed a significant improvement of LBP level without LL and sacral inclination changes. The authors of the current study noted that this lack of change may be related to the radiographic technique rather than to the actual clinical posture or gait [69].

Previous studies declared that changes in PT contribute to concomitant changes in the orientation of the acetabulum relative to the femur [29, 70, 71]. An increment in PT produces a functional increase in the anteversion of the acetabulum [58]. Conversely, a decrement in PT is accompanied by a functional decrease in acetabular anteversion [58]. For every degree added to PT, the typical acetabulum will gain 0.7° of anteversion [29, 70, 71]. This increase in acetabular anteversion, which inevitably

follows an increase of PT between standing and sitting positions, helps clear the anterior lip of the acetabulum from impingement by the femoral neck, thus preventing posterior instability as the extreme range of flexion is approached [58].

Moreover, during sit-to-stand movement, especially in the extreme range of extension, there is a decrease in PT and subsequent functional retroversion of the acetabulum, clearing the posterior lip of the acetabulum from impingement by the femoral neck, thus preventing anterior instability [58]. However, a recent study did not observe a significant relationship between sagittal imbalance parameters and THA dislocations [30]. Del-Sole et al. (2017) [72], in a retrospective study, reported that patients who suffered a THA dislocation showed a greater PI-LL, but a normal CA was identified in 80% of patients. Although the authors reported a significant relationship between PT, SS, TPA, and T_9 spinopelvic inclination with standing CA, the strength of associations was weak to moderate [72]. The results of the present study were interpreted based on the significance of *P*-values. A statistically significant correlation does not necessarily mean that the strength of the correlation is strong or high [73]. The *P*-value shows the probability that this strength may occur by chance [73]. The authors would have had to interpret the Pearson's correlation coefficients based on their strength. Haws et al. (2019) [30], in a retrospective cohort study on 29 patients with THA dislocation, found similar results and revealed that spinopelvic sagittal parameters, including LL, PI, PT, SS, and PI-LL, were not associated with CA. They concluded that the relationship between spinal deformity and dislocation rates following THA may not be because of inaccurate cup orientation [30]. The lack of relationship between CA and spinopelvic sagittal balance in THA dislocations suggests that normal anteversion targets for acetabular cup placement may not be universally applicable [30, 62]. Therefore, controversy still exists regarding placement of the acetabular cup within the Lewinnek's classic safe zone of $15^\circ \pm 10^\circ$ of anteversion and postoperative dislocation risk [30, 62, 63].

York et al. (2018) [56], in a retrospective cohort study on 468 patients undergoing THA, showed that patients with lumbar spine fusion are at increased risk for postoperative dislocations. The authors of this study expressed that lower PI and SS in lumbar spine fusion patients compared to patients without prior lumbar spine fusion may predispose these patients to dislocation after THA [56]. Previous studies have shown that each additional level of spinal fusion decreased SS change from the standing to sitting position by 1.6° [56, 74]. More likely, the altered functional biomechanics of the lumbopelvic region increase the possibility of impingement or

acetabular uncovering with subsequent dislocation [56, 75]. The sagittal orientation of the acetabular component is also related to total hip stability [76]. In a recent narrative review, Niemeier et al. (2020) pointed out that the increased CA places patients at increased risk of posterior impingement and anterior dislocation [76].

The sample size in the majority of the eligible studies was not defined a priori, and therefore future studies need to calculate sample size based on primary outcome(s) and probability of attrition rate depending on follow-up time. Moreover, the observed attrition rate should be adjusted during the statistical analysis through inverse probability weighting (IPW) [77] or multiple imputation (MI) [78]- two widely adopted approaches dealing with missing outcome data.

If a study contains outcome multiplicity, it is necessary to apply multiple comparison correction, which can greatly minimize the false positive errors [79]. Many standards of reporting (e.g., CONSORT; Consolidated Standards of Reporting Trials) recommend that primary and secondary outcomes should be specified clearly with presentation of both estimated effect size and associated confidence interval to reduce the risk for selective outcome reporting.

Future studies could assess the relationship between spinopelvic alignment changes and LBP improvement following THA as the previously published studies on this topic had serious limitations. Besides, improvement in spinal column scoliosis after THA was not investigated in many studies, and scanty information exists about the mechanism of scoliosis improvement in patients undergoing THA. Previous studies mainly focused on the lumbar region of the spine; thus, there is a need for further research to explore alignment changes in upper regions of the spine (i.e., cervical and thoracic) after THA.

Limitations and strengths

Limitations of this scoping review must be acknowledged. First, we only assessed spinopelvic alignment and LBP following THA and studies in which the enrolled participants had undergone SRA were excluded from the review. Therefore, we need to bear in mind that these results cannot be generalized to patients with SRA. Second, our findings are dependent on information extracted from individual studies, all of which have their own methodological characteristics (e.g., different study design and THA procedure) and objectives. Third, due to the nature of scoping reviews, we conducted a broad search with diverse search terms, which was a challenge. Finally, only four key databases were searched, and consequently, we may have missed some published articles. A key strength of this scoping review was its ability to provide a broad overview of

spinopelvic alignment changes following THA. Also, in this scoping review, we highlighted the essential methodological limitations that exist in the studies of this area.

Conclusions

This scoping review asked wide-ranging questions and investigated a diverse assortment of studies. Many studies reported that spinopelvic parameters such as PT and SS were changed following THA. However, the results were not consistent across the eligible studies. It has been demonstrated that patients with a THA dislocation had abnormal spinopelvic alignment compared to patients without THA dislocation. Furthermore, lumbar spine scoliosis and LBP were improved in patients undergoing THA. Several methodological issues were identified in the eligible studies, including no sample size calculation at the start of the study, no clear definition of primary and secondary outcomes, and no type-I error adjustment for multiple comparison conditions. Finally, some recommendations for future studies were provided in the last part of this paper.

Abbreviations

ADLs: activities of daily living; APP: anterior pelvic plane angle; CA: cup (acetabular) anteversion; CEBM: Oxford Centre for Evidence-Based Medicine; CENTRAL: Cochrane Central Register of Controlled Trials; CI: cup inclination; CONSORT: Consolidated Standards of Reporting Trials; FCA: functional cup anteversion; IPW: inverse probability weighting; IQR: interquartile range; LBP: low back pain; LL: lumbar lordotic; MeSH: medical subject heading; MI: multiple imputation; OA: osteoarthritis; PI: pelvic incidence; PI-LL: PI minus LL; PT: pelvic tilt; SRA: surface replacement arthroplasty; SS: sacral slope; SSA: Spinous angle; SVA: sagittal vertical axis; THA: total hip arthroplasty; TK: thoracic kyphosis.

Supplementary Information

The online version contains supplementary material available at <https://doi.org/10.1186/s12891-022-05154-7>.

Additional file 1.

Additional file 2. Characteristics of the selected studies in chronological order.

Acknowledgements

None declared.

Disclosures

- 1-All authors assure that the manuscript is an original work that has not been previously published.
- 2-All authors assure that the manuscript is not under consideration by any other publication.
- 3-All authors accept full responsibility for the accuracy of all content, including findings, citations, quotations, and references contained within the manuscript.
- 4-The authors have no conflicts of interest to declare.
- 5-There was no funding source for the present study. All authors had full access to all the data in the study.

Authors' contributions

M.P. and M.A.M. had full access to all of the data in the study and take responsibility for the integrity of the data and the accuracy of the data analysis. Study concept and design: M.P. and A.K. Acquisition of data: M.P. S.D., and M.S. Analysis and interpretation of data: M.P., A.K., and M.A.M. Writing manuscript: M.P. and J.D. Revising it critically: M.A.M.B., C.F.dLP., and M.A.M. All authors approved the final version.

Funding

None of the authors has received any funding from any commercial or non-commercial agency with regard to the preparation of this article.

Availability of data and materials

All data generated or analysed during this study are included in this published article [and its supplementary information files].

Declarations

Ethics approval and consent to participate

Not applicable.

Consent for publication

Not applicable.

Competing interests

The authors declare that they have no competing interests.

Author details

¹Rehabilitation Research Center, Department of Physiotherapy, School of Rehabilitation Sciences, Iran University of Medical Sciences, Tehran, Iran. ²Bethesda PhysioCare, Bethesda, MD, USA. ³Myopain Seminars, Bethesda, MD, USA. ⁴Department of Physical Therapy and Rehabilitation Science, School of Medicine, University of Maryland, Baltimore, MD, USA. ⁵Center for Educational Research in Medical Sciences (CERMS), Department of Medical Education, School of Medicine, Iran University of Medical Sciences, Tehran, Iran. ⁶Pediatric Neurorehabilitation Research Center, University of Social Welfare and Rehabilitation Sciences, Tehran, Iran. ⁷University Institute of Physical Therapy, Faculty of Allied Health Sciences, University of Lahore, Lahore, Pakistan. ⁸Department of Health Sciences Education Development, School of Public Health, Tehran University of Medical Sciences, Tehran, Iran. ⁹Department of Physical Therapy, Occupational Therapy, Rehabilitation and Physical Medicine, Universidad Rey Juan Carlos, Alcorcón, Madrid, Spain. ¹⁰Cátedra de Investigación y Docencia en Fisioterapia: Terapia Manual y Punción Seca, Universidad Rey Juan Carlos, Alcorcón, Madrid, Spain. ¹¹Department of Epidemiology and Biostatistics, School of Public Health, Tehran University of Medical Sciences, Poursina St., Shanzdah-e Azar St., P. O. Box: 6446-14155, Tehran, Iran.

Received: 15 October 2021 Accepted: 28 February 2022

Published online: 15 March 2022

References

1. Piazzolla A, Solarino G, Bizzoca D, Moretti B. Letter to the editor on "abnormally high dislocation rates of Total hip Arthroplasty after spinal deformity surgery". *J Arthroplast.* 2017;32:2619–20.
2. Smith JS, Shaffrey CI, Lafage V, Blondel B, Schwab F, Hostin R, Hart R, O'Shaughnessy B, Bess S, Hu SS. Spontaneous improvement of cervical alignment after correction of global sagittal balance following pedicle subtraction osteotomy: Presented at the 2012 Joint spine section meeting. *J Neurosurg Spine* 2012, 17:300–307.
3. Ochi H, Homma Y, Baba T, Nojiri H, Matsumoto M, Kaneko K. Sagittal spinopelvic alignment predicts hip function after total hip arthroplasty. *Gait Posture.* 2017;52:293–300.
4. McKnight BM, Trasolini NA, Dorr LD: Spinopelvic Motion and Impingement in Total Hip Arthroplasty. *J Arthroplasty* 2019.
5. Buckland AJ, Vigdorichik J, Schwab FJ, Errico TJ, Lafage R, Ames C, et al. Acetabular anteversion changes due to spinal deformity correction: bridging the gap between hip and spine surgeons. *JBJS.* 2015;97:1913–20.

6. Heckmann N, McKnight B, Stefl M, Trasolini NA, Ike H, Dorr LD. Late dislocation following total hip arthroplasty: spinopelvic imbalance as a causative factor. *JBJS*. 2018;100:1845–53.
7. Knight SR, Aujla R, Biswas SP. Total hip Arthroplasty-over 100 years of operative history. *Orthop Rev*. 2011;3.
8. Varacallo M, Johanson NA: Hip, Replacement. In *StatPearls* [Internet]. StatPearls Publishing; 2018.
9. Healy WL, Iorio R, Clair AJ, Pellegrini VD, Della Valle CJ, Berend KR: Complications of total hip arthroplasty: standardized list, definitions, and stratification developed by the hip society. *Clin Orthopaed Related Res* 2016, 474:357–364.
10. Learmonth ID, Young C, Rorabeck C. The operation of the century: total hip replacement. *Lancet*. 2007;370:1508–19.
11. Eguchi Y, Iida S, Suzuki C, Shinada Y, Shoji T, Takahashi K, et al. Spinopelvic alignment and low back pain after total hip replacement arthroplasty in patients with severe hip osteoarthritis. *Asian Spine J*. 2018;12:325.
12. Shimmin A: Changes in spinopelvic mobility after total hip arthroplasty. In *Orthopaedic Proceedings*. *Brit Edit Soc Bone Joint Surg*; 2018: 1–1.
13. Innmann M, Merle C, Gotterbarm T, Ewerbeck V, Beaulé P, Grammatopoulos G. Can spinopelvic mobility be predicted in patients awaiting total hip arthroplasty? A prospective, diagnostic study of patients with end-stage hip osteoarthritis. *Bone Joint J*. 2019;101:902–9.
14. Rivière C, Lazennec J-Y, Van Der Straeten C, Auvinet E, Cobb J, Muirhead-Allwood S. The influence of spine-hip relations on total hip replacement: a systematic review. *Orthopaed Traumatol Surg Res*. 2017;103:559–68.
15. Legaye J, Duval-Beaupere G. Sagittal plane alignment of the spine and gravity: a radiological and clinical evaluation. *Acta Orthop Belg*. 2005;71:213–20.
16. Kanto M, Maruo K, Tachibana T, Fukunishi S, Nishio S, Takeda Y, et al. Influence of Spinopelvic alignment on pelvic tilt after Total hip Arthroplasty. *Orthop Surg*. 2019.
17. Piazzolla A, Solarino G, Bizzoca D, Montemurro V, Berjano P, Lamartina C, et al. Spinopelvic parameter changes and low back pain improvement due to femoral neck anteversion in patients with severe unilateral primary hip osteoarthritis undergoing total hip replacement. *Eur Spine J*. 2018;27:125–34.
18. Staibano P, Winemaker M, Petruccioli D, de Beer J. Total joint arthroplasty and preoperative low back pain. *J Arthroplast*. 2014;29:867–71.
19. Colquhoun HL, Jesus TS, O'Brien KK, Tricco AC, Chui A, Zarin W, et al. Study protocol for a scoping review on rehabilitation scoping reviews. *Clin Rehabil*. 2017;31:1249–56.
20. Arksey H, O'Malley L. Scoping studies: towards a methodological framework. *Int J Soc Res Methodol*. 2005;8:19–32.
21. Levac D, Colquhoun H, O'Brien KK. Scoping studies: advancing the methodology. *Implement Sci*. 2010;5:69.
22. Tricco AC, Lillie E, Zarin W, O'Brien KK, Colquhoun H, Levac D, et al. PRISMA extension for scoping reviews (PRISMA-ScR): checklist and explanation. *Ann Intern Med*. 2018;169:467–73.
23. Sackett DL, Straus M, Richardson WS, Rosenberg W, Haynes RB. Evidence-based medicine: how to practice & teach EBM. London: Churchill Livingstone; 2000.
24. Evans JT, Evans JP, Walker RW, Blom AW, Whitehouse MR, Sayers A. How long does a hip replacement last? A systematic review and meta-analysis of case series and national registry reports with more than 15 years of follow-up. *Lancet*. 2019;393:647–54.
25. McKnight BM, Trasolini NA, Dorr LD. Spinopelvic motion and impingement in Total hip Arthroplasty. *J Arthroplast*. 2019;34:S53–s56.
26. Sultan AA, Khlopas A, Piuze NS, Chughtai M, Sodhi N, Mont MA. The impact of spino-pelvic alignment on total hip arthroplasty outcomes: a critical analysis of current evidence. *J Arthroplast*. 2018;33:1606–16.
27. An VV, Phan K, Sivakumar BS, Mobbs RJ, Bruce WJ. Prior lumbar spinal fusion is associated with an increased risk of dislocation and revision in total hip arthroplasty: a meta-analysis. *J Arthroplast*. 2018;33:297–300.
28. Tezuka T. The effect of pelvic inclination angle on cup position and polyethylene Wear after Total hip Arthroplasty. *Japan J Joint Dis*. 2014;33:49–54.
29. Maratt JD, Esposito CI, McLawhorn AS, Jerabek SA, Padgett DE, Mayman DJ. Pelvic tilt in patients undergoing total hip arthroplasty: when does it matter? *J Arthroplast*. 2015;30:387–91.
30. Haws BE, Khechen B, Patel DV, Louie PK, Iyer S, Cardinal KL, et al. Sagittal imbalance does not influence cup Anteversion in Total hip Arthroplasty dislocations. *Clin Spine Surg*. 2019;32:E31–6.
31. Okanou Y, Ikeuchi M, Takaya S, Izumi M, Aso K, Kawakami T. Chronological changes in functional cup position at 10 years after total hip arthroplasty. *Hip International*. 2017;27:477–82.
32. Eyvazov K, Eyvazov B, Basar S, Nasto LA, Kanatli U. Effects of total hip arthroplasty on spinal sagittal alignment and static balance: a prospective study on 28 patients. *Eur Spine J*. 2016;25:3615–21.
33. Ishida T, Inaba Y, Kobayashi N, Iwamoto N, Yukizawa Y, Choe H, et al. Changes in pelvic tilt following total hip arthroplasty. *J Orthop Sci*. 2011;16:682–8.
34. Keshmiri A, Schröter C, Weber M, Craiovan F, Grifka J, Renkawitz T. No difference in clinical outcome, bone density and polyethylene wear 5–7 years after standard navigated vs. conventional cementfree total hip arthroplasty. *Arch Orthop Trauma Surg* 2015, 135:723–730.
35. Suzuki H, Inaba Y, Kobayashi N, Ishida T, Ike H, Saito T. Postural and chronological change in pelvic tilt five years after total hip arthroplasty in patients with developmental dysplasia of the hip: a three-dimensional analysis. *J Arthroplast*. 2016;31:317–22.
36. Cotter BD, Innmann MM, Dobransky JS, Merle C, Beaulé PE, Grammatopoulos G. Does functional cup orientation change at minimum of 10 years after primary total hip arthroplasty? *J Arthroplast*. 2020;35:2507–12.
37. Hagiwara S, Orita S, Nakamura J, Inage K, Kawasaki Y, Shiko Y, et al. Impact of spinal alignment and stiffness on impingement after total hip arthroplasty: a radiographic study of pre-and post-operative spinopelvic alignment. *Eur Spine J*. 2021;30:2443–9.
38. Homma Y, Ishii S, Yanagisawa N, Ochi H, Baba T, Nojiri H, et al. Pelvic mobility before and after total hip arthroplasty. *Int Orthop*. 2020;44:2267–74.
39. Okuzu Y, Goto K, Kuroda Y, Kawai T, Matsuda S. Preoperative factors associated with low Back pain improvement after Total hip Arthroplasty in a Japanese population. *J Arthroplast*. 2021.
40. Lin YH, Lin YT, Chen KH, Pan CC, Shih CM, Lee CH. Paradoxical spinopelvic motion: does global balance influence spinopelvic motion in total hip arthroplasty? *BMC Musculoskelet Disord*. 2021;22.
41. Weng W, Wu H, Wu M, Zhu Y, Qiu Y, Wang W. The effect of total hip arthroplasty on sagittal spinal-pelvic-leg alignment and low back pain in patients with severe hip osteoarthritis. *Eur Spine J*. 2016;25:3608–14.
42. Radcliff KE, Orozco F, Molby N, Delsotta L, Chen E, Post Z, et al. Change in spinal alignment after total hip arthroplasty. *Orthop Surg*. 2013;5:261–5.
43. Blondel B, Parratte S, Tropiano P, Pauly V, Aubaniac J-M, Argenson J-N. Pelvic tilt measurement before and after total hip arthroplasty. *Orthopaed Traumatol Surg Res*. 2009;95:568–72.
44. DiGioia III AM, Hafez MA, Jaramaz B, Levison TJ, Moody JE: Functional pelvic orientation measured from lateral standing and sitting radiographs. *Clin Orthopaed Related Res* 2006, 453:272–276.
45. Esposito CI, Carroll KM, Sculco PK, Padgett DE, Jerabek SA, Mayman DJ. Total hip arthroplasty patients with fixed spinopelvic alignment are at higher risk of hip dislocation. *J Arthroplast*. 2018;33:1449–54.
46. Murphy WS, Klingenstein G, Murphy SB, Zheng G: Pelvic tilt is minimally changed by total hip arthroplasty. *Clin Orthopaed Related Res* 2013, 471:417–421.
47. Nishihara S, Sugano N, Nishii T, Ohzono K, Yoshikawa H: Measurements of pelvic flexion angle using three-dimensional computed tomography. *Clin Orthopaed Related Res* (1976–2007) 2003, 411:140–151.
48. Polkowski GG, Nunley RM, Ruh EL, Williams BM, Barrack RL: Does standing affect acetabular component inclination and version after THA? *Clin Orthopaed Related Res* 2012, 470:2988–2994.
49. Zhu J, Wan Z, Dorr LD: Quantification of pelvic tilt in total hip arthroplasty. *Clin Orthopaed Related Res* 2010, 468:571–575.
50. Nam D, Riegler V, Clohisy JC, Nunley RM, Barrack RL. The impact of total hip arthroplasty on pelvic motion and functional component position is highly variable. *J Arthroplast*. 2017;32:1200–5.
51. Klemm C, Limmahakhun S, Bounajem G, Xiong L, Yeo J, Kwon Y-M. Effect of postural changes on in vivo pelvic tilt and functional component anteversion in total hip arthroplasty patients with lumbar disc degenerations. *Bone Joint J*. 2020;102:1505–10.
52. Limmahakhun S, Box HN, Arauz P, Hennessy DW, Klemm C, Kwon YM: In Vivo analysis of spinopelvic kinematics and peak head-cup contact in total hip arthroplasty patients with lumbar degenerative disc disease. *J Orthopaedic Res* 2019, 37:674–680.
53. Saiki F, Tanaka T, Tachibana N, Oshima H, Kaneko T, Horii C, Nakamoto H, Kato S, Doi T, Matsubayashi Y, et al: Effect of Spinal Alignment Changes on Lower Back Pain in Patients Treated with Total Hip Arthroplasty for Hip Osteoarthritis. *Medicina (Kaunas, Lithuania)* 2021, 57.

54. Ike H, Bodner RJ, Lundergan W, Saigusa Y, Dorr LD. The effects of pelvic incidence in the functional anatomy of the hip joint. *J Bone Joint Surg Am.* 2020;102:991–9.
55. Parvizi J, Pour AE, Hillibrand A, Goldberg G, Sharkey PF, Rothman RH. Back pain and total hip arthroplasty: a prospective natural history study. *Clin Orthop Relat Res.* 2010;468:1325–30.
56. York PJ, McGee AW, Dean CS, Hellwinkel JE, Kleck CJ, Dayton MR, et al. The relationship of pelvic incidence to post-operative total hip arthroplasty dislocation in patients with lumbar fusion. *Int Orthop.* 2018;42:2301–6.
57. Furuichi S, KURODA T, MITANI S, NANBA Y, KAWAMOTO T, UMEHARA N. Changes in sagittal spino-pelvic alignment after total hip arthroplasty using the Roussouly classification. *Kawasaki Med J.* 2016;42:57–65.
58. Parilla FW, Shah RR, Gordon AC, Mardjetko SM, Cipparrone NE, Goldstein WM, Goldstein JM: Does it matter: Total hip Arthroplasty or lumbar spinal fusion first? Preoperative Sagittal Spinopelvic Measurements Guide Patient-Specific Surgical Strategies in Patients Requiring Both. *J Arthroplasty* 2019.
59. Taki N, Mitsugi N, Mochida Y, Akamatsu Y, Saito T. Change in pelvic tilt angle 2 to 4 years after total hip arthroplasty. *J Arthroplast.* 2012;27:940–4.
60. Tamura S, Nishihara S, Takao M, Sakai T, Miki H, Sugano N. Does pelvic sagittal inclination in the supine and standing positions change over 10 years of follow-up after total hip arthroplasty? *J Arthroplast.* 2017;32:877–82.
61. Tripuraneni KR, Munson NR, Archibeck MJ, Carothers JT. Acetabular abduction and dislocations in direct anterior vs posterior total hip arthroplasty: a retrospective, matched cohort study. *J Arthroplast.* 2016;31:2299–302.
62. Abdel MP, von Roth P, Jennings MT, Hanssen AD, Pagnano MW. What safe zone? The vast majority of dislocated THAs are within the Lewinnek safe zone for Acetabular component position. *Clin Orthop Relat Res.* 2016;474:386–91.
63. Murphy WS, Yun HH, Hayden B, Kowal JH, Murphy SB. The safe zone range for cup anteversion is narrower than for inclination in THA. *Clin Orthop Relat Res.* 2018;476:325.
64. Caglar O, Isik S, Kaymakoglu M, Demirkiran HG, Atila B, Tokgozoglu M, et al. Sagittal spinal alignment after total hip arthroplasty for neglected high hip dysplasia: does changing the distorted mechanics of the hip normalize spinal alignment? *Spine Deformity.* 2021;9:221–9.
65. Can A, Erdoğan F, Yontar NS, Erdoğan AÖ, Erdem MN, Sarıkaya İA. Spinopelvic alignment does not change after bilateral total hip arthroplasty in patients with bilateral Crowe type-IV developmental dysplasia of the hip. *Acta Orthop Traumatol Turc.* 2020;54:583.
66. Carender CN, Meyer MD, Wynn MS, Bedard NA, Otero JE, Brown TS. The prevalence of abnormal spinopelvic relationships in patients presenting for primary total hip arthroplasty. *Arthroplasty Today.* 2020;6:381–5.
67. Lazennec J-Y, Boyer P, Gorin M, Catonné Y, Rousseau MA: Acetabular anteversion with CT in supine, simulated standing, and sitting positions in a THA patient population. *Clinical Orthopaedics and Related Research*® 2011, 469:1103–1109.
68. Pourahmadi M, Delavari S, Koes B, Keshtkar A, Nazempour M, Mansournia MA: How to formulate appropriate review questions for systematic reviews in sports medicine and rehabilitation? , vol. 55. pp. 1246–1247: *Brit J Sports Med*; 2021:1246–1247.
69. Ben-Galim P, Ben-Galim T, Rand N, Haim A, Hipp J, Dekel S, et al. Hip-spine syndrome: the effect of total hip replacement surgery on low back pain in severe osteoarthritis of the hip. *Spine.* 2007;32:2099–102.
70. Lembeck B, Mueller O, Reize P, Wuelker N. Pelvic tilt makes acetabular cup navigation inaccurate. *Acta Orthop.* 2005;76:517–23.
71. Wan Z, Malik A, Jaramaz B, Chao L, Dorr LD. Imaging and navigation measurement of acetabular component position in THA. *Clin Orthop Relat Res.* 2009;467:32–42.
72. DeSole EM, Vigdorich JM, Schwarzkopf R, Errico TJ, Buckland AJ. Total hip arthroplasty in the spinal deformity population: does degree of sagittal deformity affect rates of safe zone placement, instability, or revision? *J Arthroplast.* 2017;32:1910–7.
73. Akoglu H. User's guide to correlation coefficients. *Turkish J Emerg Med.* 2018;18:91–3.
74. Lazennec JY, Clark IC, Folinis D, Tahar IN, Pour AE. What is the impact of a spinal fusion on acetabular implant orientation in functional standing and sitting positions? *J Arthroplast.* 2017;32:3184–90.
75. McCollum DE, Gray WJ: Dislocation after total hip arthroplasty. Causes and prevention. *Clin Orthop Relat Res* 1990:159–170.
76. Niemeier TE, Wills BW, Theiss SM, Strom SF. Sagittal pelvic kinematics in hip Arthroplasty. *Curr Reviews Musculoskeletal Med.* 2020;13:240–6.
77. Mansournia MA, Altman DG. Inverse probability weighting. *Bmj.* 2016;352:i189.
78. Little RJ, Rubin DB. *Statistical analysis with missing data.* New Jersey: John Wiley & Sons; 2019.
79. Qin N, Zhang J, Zhang W, Dai J, Chen W. Some tips about statistics on medical research. *J Thoracic Disease.* 2015;7:E177.
80. Katz EA, Katz SB, Fedorchuk CA, Lightstone DF, Banach CJ, Podoll JD. Increase in cerebral blood flow indicated by increased cerebral arterial area and pixel intensity on brain magnetic resonance angiogram following correction of cervical lordosis. *Brain Circulation.* 2019;5:19.
81. Xu-hui Z, Jia-hu F, Lian-shun J, Zhi-yong C, Yong Z, Xiong-sheng C, et al. Clinical significance of cervical vertebral flexion and extension spatial alignment changes. *Spine.* 2009;34:E21–6.
82. Vaughn DW, Brown EW. The influence of an in-home based therapeutic exercise program on thoracic kyphosis angles. *J Back Musculoskeletal Rehabil.* 2007;20:155–65.
83. Been E, Kalichman L. Lumbar lordosis. *Spine J.* 2014;14:87–97.
84. Weiss H-R, Negrini S, Rigo M, Kotwicki T, Hawes MC, Grivas TB, et al. Indications for conservative management of scoliosis (guidelines). *Scoliosis.* 2006;1:5.
85. Sarwark J, Castelein R, Maqsood A, Aubin C-E. The biomechanics of induction in adolescent idiopathic scoliosis. *J Bone Joint Surg.* 2019;101.
86. Sure DR, LaBagnara M, Smith JS, Shaffrey CI: Defining adult lumbar scoliosis. In *Adult Lumbar Scoliosis.* Springer; 2017: 1–9.
87. Yang M, Yang C, Xu Z, Chen Z, Wei X, Zhao J, et al. Role of T1 pelvic angle in Assessing sagittal balance in outpatients with unspecific low Back pain. *Medicine.* 2016;95.
88. Yang M, Yang C, Ni H, Zhao Y, Li M. The relationship between T1 sagittal angle and sagittal balance: a retrospective study of 119 healthy volunteers. *PLoS One.* 2016;11:e0160957.
89. Hanke LF, Tuakli-Wosornu YA, Harrison JR, Moley PJ. The relationship between sacral slope and symptomatic isthmic spondylolysis in a cohort of high school athletes: a retrospective analysis. *PM&R.* 2018;10:501–6.
90. Vialle R, Levassor N, Rillardon L, Templier A, Skalli W, Guigui P. Radiographic analysis of the sagittal alignment and balance of the spine in asymptomatic subjects. *JBJS.* 2005;87:260–7.
91. Albers CE, Hanke MS, Ecker TM, Haefeli PC, Siebenrock KA, Steppacher SD, Zurmühle CA, Schwab JM, Tannast M: Computer Assisted Diagnosis and Treatment Planning of Femoroacetabular Impingement (FAI). In *Computational Radiology for Orthopaedic Interventions.* Springer; 2016: 173–196.
92. Hosogane N, Watanabe K, Yagi M, Kaneko S, Toyama Y, Matsumoto M. Scoliosis is a risk factor for Gastroesophageal reflux disease in adult spinal deformity. *Clin Spine Surg.* 2017;30:E480–4.
93. Sellami M, Hamdi W, Riahi H, Maatallah K, Ferjani H, Kaffel D, et al. THU0402 CONTRIBUTION of the EOS imaging system in ASSESSING pelvic and spinal deformities in SPONDYLOARTHRITIS. *Ann Rheum Dis.* 2019;78:487–8.
94. Barry C, Jund JM, Noseda O, Roussouly P: Sagittal balance of the pelvis-spine complex and lumbar degenerative diseases. A comparative study about 85 cases. *Eur Spine J* 2007, 16:1459–1467.
95. Vanrusselt J, Vansevenant M, Vanderschueren G, Vanhoenacker F. Postoperative radiograph of the hip arthroplasty: what the radiologist should know. *Insights Imaging.* 2015;6:591–600.
96. Dardenne G, Hamitouche C, Stindel E, Roux C: Ultrasound imaging-based procedure to integrate the dynamic behavior of the pelvis in Total Hip Arthroplasty planning. In 2008 5th IEEE international symposium on biomedical imaging: from Nano to macro. IEEE; 2008: 1187–1190.
97. Lazennec J-Y, Charlot N, Gorin M, Roger B, Arafati N, Bissery A, et al. Hip-spine relationship: a radio-anatomical study for optimization in acetabular cup positioning. *Surg Radiol Anat.* 2004;26:136–44.
98. Sutter EG, Wellman SS, Bolognesi MP, Seyler TM. A geometric model to determine patient-specific cup Anteversion based on pelvic motion in Total hip Arthroplasty. *Adv Orthopedics.* 2019;2019.

Publisher's Note

Springer Nature remains neutral with regard to jurisdictional claims in published maps and institutional affiliations.